

Vagal schwannoma of the posterior mediastinum with cervical extension

Vagal schwannoma with cervical extension

Hidir Esme¹, Mustafa Calik¹, Saniye Goknil Calik²

¹Department of Thoracic Surgery, Health Sciences University, Konya Training and Research Hospital,

²Department of Emergency and First Aid, KTO Karatay University, Vocational School of Health Services, Konya, Turkey

This case was presented as a poster presentation in the American College of Chest Physicians CHEST 2017 28 October-1 November 2017 Toronto, Ontario, Canada and published as a supplement in the CHEST Journal October 2017; Volume 152, Issue 4, Supplement, Page A42-A43 DOI: 10.1016/j.chest.2017.08.073

Abstract

A 35-year-old male was admitted to our Emergency Department with chest pain and hoarseness lasting for a month. A well-defined 58x36x34 mm mass located in the left posterior mediastinum with cervical extension was found on radiological imaging. It was completely excised with transversal cervicotomy and left-sided video-assisted thoracoscopic surgery. Schwannomas originating from the intrathoracic vagus nerve are extremely rare. Due to its rarity, similarity with other mediastinal lesions and unusual localization, diagnosis can be missed easily in busy and crowded Emergency Department. Here, the essence of diagnosis is to exclude other causes and keep in mind.

Keywords

Schwannoma; Nervus Vagus; Cervical; Mediastinum; Video-Assisted Thoracoscopic Surgery

DOI: 10.4328/ACAM.6115 Received: 09.12.2018 Accepted: 02.01.2019 Published Online: 05.01.2019 Printed: 01.11.2019 Ann Clin Anal Med 2019;10(6): 765-8
Corresponding Author: Mustafa Calik, Department of Thoracic Surgery, Health Sciences University, Konya Training and Research Hospital, Meram, Konya, Turkey.
T.: +90 3323236709 F.: +90 3323236723 E-Mail: drmcalik@hotmail.com
ORCID ID: <https://orcid.org/0000-0001-9963-5724>

Introduction

Schwannoma is a tumor that arises from the Schwann cells surrounding the peripheral nerve fibres of either the nerve roots or peripheral nerves. Most of them are benign tumors and are found in the posterior mediastinum at the level of the paravertebral gutter, originating from the root of an intercostal or sympathetic nerve [1]. The rate of schwannoma originating from the vagus nerve within the mediastinum is low, consisting of only 1.4% of intrathoracic schwannomas [2]. An unusual cervicomedial schwannoma of the left vagus nerve that was resected completely by transversal cervicotomy and left thoracotomy has been reported in this case.

Case Report

A 35-year-old male was admitted to the Emergency Department with chest pain and hoarseness lasting for a month. The patient's history was not consequential. No considerable abnormalities, including those in carcinoembryonic antigen and α -fetoprotein levels, were not revealed in the physical examination and laboratory test results. A well-defined mass located in the left posterior lung field, bulging out of the mediastinum was exhibited in the chest roentgenogram (Figure 1). A clearly demarcated, encircled mass, ~58x36x34 mm in size, in the left posterior mediastinum with the cervical extension was found in the contrast-enhanced computed tomography of the chest (Figure 2A, B and C). Positron emission tomography was not performed because the patient is not considered to have a malignant tumor.

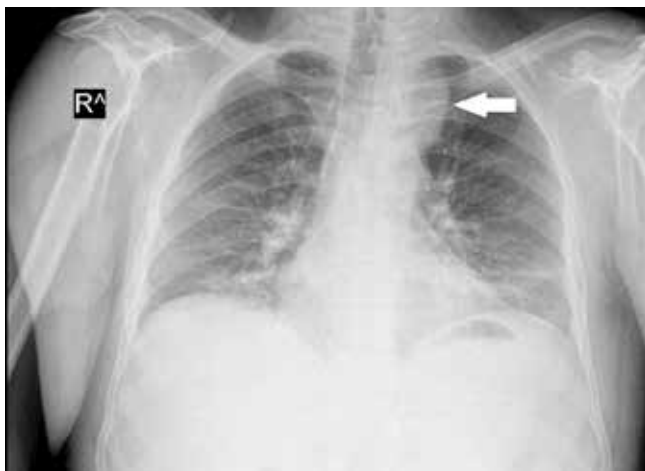

Figure 1. Posteroanterior chest X-Ray showing a left posterior lung field mass protruding from the mediastinum (White Arrow).

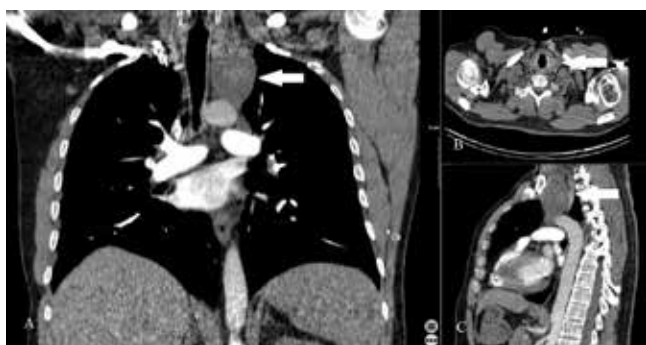


Figure 2. (A) Coronal (B) Axial and (C) Sagittal views of the contrast-enhanced computed thorax tomography is showing the circumscribed mass identifiable (58x36x34mm) in the left posterior mediastinum with a smooth and clear margin (White Arrow).

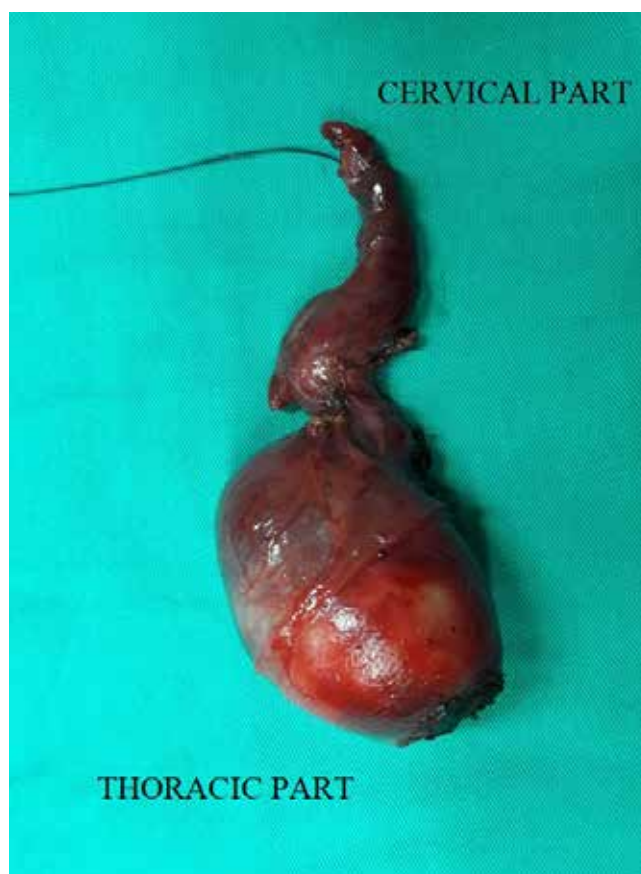

Figure 3. Postoperative view of the schwannoma showing the tumor originating from, and encasing the vagus nerve.

The patient went through the left-sided video-assisted thoracoscopic surgery (VATS). During the surgery, a large tumor with a round shape was detected in the left posterior mediastinum. A tumor stemmed from the vagus nerve and encased it (Figure 3). The mass was standing in the anterior and superior to the aortic arch, and extended to the cervical region. It was adjacent to the left subclavian artery, left common carotid artery, and left innominate vein as it was seen in the imagings, but it was not invasive (Figure 2). The intrathoracic mass was separated from the surrounding tissues and removed easily and completely because of the intact tumor capsule except for the nervus vagus. It completely wrapped the nervus vagus and it was impossible for us to separate (Figure 3). However, a piece of the mass extended to the cervical region. A suprasternal cervical approach was employed to remove it completely. During the operation, the patient was closely observed in terms of the severe cardiac rhythm abnormalities including bradycardia and asystole.

Histological examination showed that the tumor was consistent with a benign schwannoma of the vagus nerve, characterized by a proliferation of spindle cells with cellular uniformity and immunoreactivity to S-100 protein. During the perioperative time no complications were observed. The chest tube was removed on the fourth postoperative day. After 24 hours, the patient was discharged without any postoperative complications. Eighteen months follow-up at two-month intervals the patient had a symptom-free tumour but presented hoarseness. The patient was consulted at the ear, nose, and throat (ENT) clinic for this complaint. Follow-up treatment of the patient is performed in the ENT clinic. Written informed consent was obtained from the patient who participated in this study.

Discussion

Schwannoma, also called neurilemmoma, is a type of benign nerve sheath tumor that originates from Schwann cells. Usually, they are found in the head, neck, and extremities. They may also present within the thorax, originating in the sympathetic chain, spinal nerve roots, intercostal nerves, brachial plexus, phrenic nerve or vagus nerve [2]. Schwannomas of the vagus nerve are almost twice more likely to be located on the left than on the right, as the recurrent laryngeal nerve arises lower in the thoracic cavity on the left side and the left nerve trunk is thicker [3]. In our case, both recurrent laryngeal and vagus nerve involvement are exceptional.

Up to 80% of cases are asymptomatic, and it is mostly diagnosed by accident in young and middle-aged adults. Symptoms occur due to local compression of the affected nerve or adjacent structures [4]. When a tumour is affected by the recurring laryngeal nerve, hoarseness may occur. When a tumour encases the vagal nerve, enucleation of the schwannoma from the vagal nerve is difficult and amputation of the nerve is inevitable with the sacrifice of the recurrent laryngeal nerve branch, as has been shown in the present case. Postoperative hoarseness continues. Diagnosis is frequently evoked by the accidental discovery of abnormalities on chest radiography. Some enormous forms may become indicative of compression of adjacent structures such as trachea or oesophagus. Currently, MRI is the inspection of choice to define better the characteristics of the tumor and its limitations [5, 6]. Macroscopically, schwannomas seem as an encapsulated tumor, well limited and imitating spheroidal lobulated masses as in our case (Figure 3).

Surgical resection is recommended for mediastinal neurogenic tumors. Thoracotomy has not the usual approach for these tumors since the early 1990s. Thirty years ago we witnessed the first steps of VATS. Less invasive, less and smaller incisions ideas were easily adopted by thoracic surgeons. Increasingly, it has been extensively accepted and implemented worldwide. Various techniques have been developed for VATS and evolved over the past years. Recently, uniportal VATS with subxiphoid incision has been introduced. Sophisticated instruments and innovative technology have been developed to cope with the tough requirement of VATS. In order to overcome these disadvantages and necessity, robotic systems have been begun to develop since 1993. The first robotic-assisted thoracic surgery (RATS) systems, Zeus® (Computer Motion Inc, Goleta, CA, USA) and da Vinci® (da Vinci Surgical System Sunnyvale, CA, USA), were developed simultaneously and approved by the US Food and Drug Administration minimally invasive surgery. Today, da Vinci Surgical System is the only commercial surgical system applied in a wide range of surgery, including urology, gynecology, thoracic and cardiovascular surgery. RATS has advantages over conventional and/or modified VATS such as binocular vision provides depth perception, advanced optical resolution for narrow anatomical areas and recreates human hand sensitivity that is lost in the course of VATS [6].

Fortunately, nowadays VATS and newly RATS which are not considered expensive or experimental are the common surgery technique for (anterior, posterior) mediastinal tumors including schwannomas such as in our case. Published outcomes and results are encouraging. Nearly all benign nerve sheath tumors as

in our case can always be excised videothoroscopically. Simply, considered to be malignant or previously proven to be malignant with a biopsy, larger than six cm and “dumbbell” tumors extending into the intervertebral foramina should be treated with an open approach [6]. On the contrary to the literature, it has been reported that thoracic neurogenic tumor could be removed up to 7.8 cm without complications [5].

In our case, the tumor was smaller than six cm but close to the large vessels. VATS provides lesser trauma and pain, shorter chest drainage time, reduced hospitalization, faster recovery, lower complication rate, better cosmetic effect, and preservation of pulmonary functions in a short term. However, VATS is not quite perfect. Disadvantages are declining binocular vision and limited mobility, an unstable camera platform and weak ergonomics of the surgeon. Mediastinal schwannomas with cervical extension raise problems of exposure because of the restricted accessibility of conventional approaches, such as conventional thoracotomy and VATS/RATS, to the cervical region [6]. Ladas [7] has described a cervical trans-sternal approach, which consists of a vertical cervicotomy along the anterior border of the sternocleidomastoid muscle pursued by a manubriotomy. We think that some giant schwannomas with cervical extension can be treated by the transverse cervical approach with VATS which avoids morbidities attributed to cervicothoracic approaches.

Pathological examination is required for the specific diagnosis of schwannoma. In the present case, histological examination revealed that the tumour was consistent with a benign schwannoma of the vagus nerve, characterized by a proliferation of spindle cells with cellular uniformity and immunoreactivity to S-100 protein. If atypical, mitoses, pleomorphism and necrosis are identified, malignant schwannoma should be considered in the diagnosis, although they are extremely rare [6].

In conclusion, due to its rarity, the similarity with other lesions and unusual localization, diagnosis can be missed easily in busy and crowded Emergency Department. It can clearly and easily be ruled out based only on clinical and imaging techniques, including computed tomography and magnetic resonance imaging, which are important in differential and definitive diagnosis of mediastinal tumors. Here, the essence of diagnosis is to exclude other causes and keep it in mind. The giant schwannomas with cervical extension can be treated by the transverse cervical approach with VATS or RATS which prevents morbidities related to cervicothoracic approaches. The prognosis of schwannoma of the vagus nerve following complete resection of the tumour seems to be satisfactory. The patient mentioned in the present case had no symptoms or signs of recurrence in the eighteen-month follow-up.

Scientific Responsibility Statement

The authors declare that they are responsible for the article's scientific content including study design, data collection, analysis and interpretation, writing, some of the main line, or all of the preparation and scientific review of the contents and approval of the final version of the article.

Animal and human rights statement

All procedures performed in this study were in accordance with

the ethical standards of the institutional and/or national research committee and with the 1964 Helsinki declaration and its later amendments or comparable ethical standards. No animal or human studies were carried out by the authors for this article.

Conflict of interest

None of the authors received any type of financial support that could be considered potential conflict of interest regarding the manuscript or its submission.

References

1. Embun Flor R, Garcia Tirado FJ, Rivas de Andres JJ. Tumores del mediastino. In: Villasante C, editor. *Enfermedades Respiratorias*. 2th ed Madrid: Aula Médica; 2011. (47): 887–904. DOI: 10.1016/j.arbr.2011.02.005
2. Heras F, Ramos G, Castaneda M, Cortejoso A, Duque JL, Yustemg. Schwannoma of the intrathoracic vagus nerve. *Arch Bronconeumol*. 1997; 33 (7): 360-2. DOI:10.1016/S0300-2896(15)30586-X
3. Huang T.W, Yang M.H, Cheng Y.L, Tsai W.C, Lee S.C. Vagus nerve schwannoma in the middle mediastinum. *Thorac Cardiovasc Surg*. 2010; 58: 312- 14. DOI: 10.1055/s-0029-1185595
4. Rodríguez CM, Naranjo S, Carbajo M. Schwannoma intratorácico del nervio vago. *Arch Bronconeumol*. 2015; 51: 255–6. DOI: 10.1016/j.arbres.2014.06.015. Epub 2014 Aug 17.
5. Wu Z, Shi M, Wan H, Gao W, Liu H, Wang, Z, Li Q. Thoracoscopic resection of a vagal schwannoma in the superior mediastinum: A case report. *Oncology letters*. 2014; 8: (1) 461-3. DOI: 10.3892/ol.2014.2116
6. Melfi F.M, Fanucchi O, Davini F, Muss A. VATS-Based Approach For Robotic Lobectomy *Thorac Surg Clin*. 2014; 24: 143–9 . DOI:10.1016/j.thorsurg.2014.02.003
7. Ladas G, Rhys-Evans PH, Goldstraw P. Anterior cervical-transsternal approach for resection of benign tumors at the thoracic inlet. *Ann Thorac Surg*. 1999; 67: 785-9. DOI:10.1016/S0003-4975(98)01323-X

How to cite this article:

Esme H, Calik M, Calik SG. Vagal schwannoma of the posterior mediastinum with cervical extension. Ann Clin Anal Med 2019;10(6): 765-8.