



Chylothorax: A Rare Complication of Endoscopic Thoracic Sympathectomy

Şilotoraks: Endoskopik Torasik Sempatektominin Nadir Bir Komplikasyonu

Mustafa Çalık¹, Hıdır Esmel¹, Taha Tahir Bekçil², Saniye Göknil Çalık³

Abstract / Öz

Hyperhidrosis (HH) is a pathological condition of excessive secretion of the eccrine sweat glands in amounts greater than that required for physiological needs. Herein, we describe a patient who was treated with autologous blood pleurodesis for ductus thoracicus injury after endoscopic thoracic sympathectomy. A 23-year-old woman was admitted to our clinic with a complaint of bilateral pronounced axillary HH, minimal sweating of the hands, and bruising. She underwent bilateral thoracic sympathectomy at levels T3 and T4. A milky fluid was observed in the left chest tube and was diagnosed as chylothorax. No similar case of postoperative chylothorax treated with autologous blood pleurodesis has been found in the English literature. According to anatomical variations, the ductus thoracicus is susceptible to injury even in the hands of an experienced surgeon. In case an injury has occurred shortly after thoracic sympathectomy, autologous blood pleurodesis is an effective treatment for chylothorax. This procedure is safe and cheap and can be easily performed at the bedside.

Keywords: Chylothorax, Thoracic, Sympathectomy, Pleurodesis, Autologous Blood

Terleme, vücut sıcaklığını sabit tutulmasında önemli bir mekanizmadır. Hiperhidrozis ekrin ter bezlerin fizyolojik ihtiyaçları için gerekli olandan daha fazla miktarlarda aşırı ter salgılanması durumudur. Burada, torakal sempatektomi sonrası gelişen ve otolog kan plöreziyiyle tedavi edilen vakayı sunduk. 23 yaşında bayan hasta aksillada daha belirgin olmak üzere ellerde minimal terleme; soğukta morarma şikâyeti ile kliniğimize başvurdu. Hastaya T3-T4 seviyesinden bilateral torakal sempatektomi yapıldı. Sol göğüs tüpünde süt gibi bir sıvı gözlemlendi ve şilotoraks teşhisi kondu. İngilizce literatür taramasında otolog kan ile plöredezis yapılan başka bir vakaya rastlamadık. Duktus torasikusun anatomik varyasyonları nedeniyle en deneyimli cerrahin elinde bile yaralanma açıktır. Torakal sempatektomiden sonra hemen sonra gelişen şilotoraks için otolog kanla yapılan plöredezis etkili bir tedavi yöntemidir. Bu işlem ucuz, kolay ve hasta başında rahatlıkla yapılabilecek bir tedavidir.

Anahtar Kelimeler: Şilotoraks, Torasik, sempatektomi, Plöredez, Otolog Kan

This study was presented in the American College of Chest Physicians CHEST Congress (October 26-31, 2013, Chicago, USA)

ORCID IDs of all the authors: 50000-0001-9963-5724; H.E. 0000-0002-6569-8193; T.T.B. 0000-0002-5705-8452; S.G.Ç. 0000-0002-6569-8193.

¹Department of Thoracic Surgery, Health Sciences University, Konya Training and Research Hospital, Konya, Turkey.

²Department of Pulmonary Medicine, Health Sciences University, Konya Training and Research Hospital, Konya, Turkey.

³Emergency and First Aid Program, Vocational School of Health Services KTO Karatay University, Konya, Turkey.

Address for Correspondence/Yazışma Adresi:

Mustafa Çalık
E-mail: drmcalik@hotmail.com

Received/Geliş Tarihi: 16.04.2017

Accepted/Kabul Tarihi: 28.10.2017

© Telif Hakkı 2018 Makale metnine istanbulmedj.org web sayfasından ulaşılabilir.

© Copyright 2018 by Available online at istanbulmedicaljournal.org

Introduction

Hyperhidrosis (HH) is a pathological condition of excessive secretion of the eccrine sweat glands in amounts greater than that required for physiological needs. HH occurs more commonly in women and is usually bilateral and symmetrical. It often begins in early childhood and usually persists throughout adulthood, resulting in severe occupational, emotional, and social disabilities (1). Although the prevalence of HH is thought to be low, it has been reported as 2.8% in the United States and 4.9% in China (2). Various treatment methods have been recommended for HH. Generally, the preferred treatment method varies according to the clinician. The success and compliance rates of medical treatments are significantly lower, particularly in patients with life-long or moderate to severe HH. Permanent management can be achieved through invasive techniques such as sympathectomy. Except for one series, no mortality has been reported, with a morbidity not exceeding 5%, in the English literature. Pneumothorax is the most common complication (2% of patients; a total of 25%-30% exclusively require thoracic drainage), followed by subcutaneous emphysema (1%) and pleural effusion (0.3%-0.5%), which rarely requires drainage. Solitary cases of complications, such as chylothorax, hemopericardium, lesions of the superior intercostal vein, pulmonary edema, or brachial plexus lesions, have been reported in a previous study (1). Herein, we describe a patient who was treated with autologous blood pleurodesis for ductus thoracicus injury after endoscopic thoracic sympathectomy.

Case Report

A 23-year-old woman was admitted to our clinic with a complaint of bilateral pronounced axillary HH, minimal sweating of the hands, and bruising. She underwent bilateral thoracic sympathectomy at levels T3 and T4 via a diathermy hook inserted through the thoracoscope (Karl Storz Hopkins 0° 26034 AA Laparoscope Tuttlingen, Germany). Electrocautery ablation of the accessory nerve and Kuntz branches was composed of approximately 3 cm to prevent recurrence at the level of the third rib. Chest X-ray was obtained in the recovery room after surgery to verify full

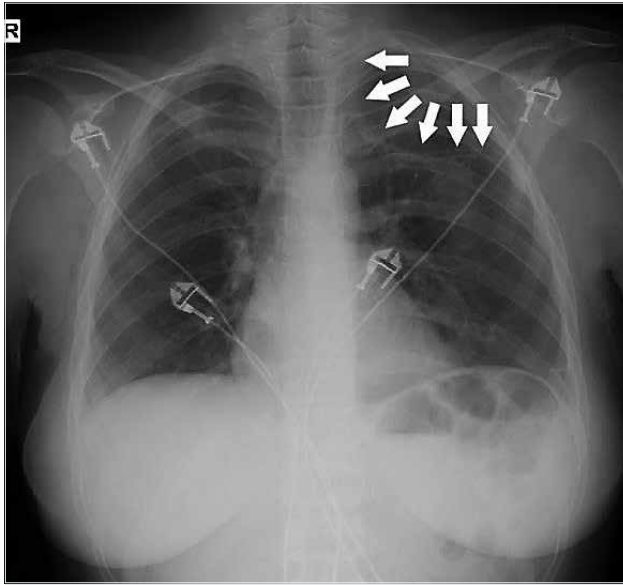


Figure 1. The patient's chest X-ray was obtained in the recovery room after surgery to verify the full expansion of the lung (Chest tube was indicated by white arrows)

expansion of the lung (Figure 1). Then, the patient was transferred to the intensive care unit (ICU). Oral nutrition was initiated 6 h after surgery. Four hours after initiating enteral feeding, a leakage of 100 mL milky fluid was observed in the left chest tube. In the biochemical assessment of the pleural drainage fluid, 12 mg/dL of cholesterol and 310 mg/dL of triglyceride were noted. The patient was diagnosed with postoperative chylothorax. Enteral feeding was terminated. She was treated with total parenteral nutrition via a central venous catheter. The right pleural drain was removed after the first postoperative day. Daily pleural drainage was 60 mL on the second day and 40 mL on the third day. A follow-up of blood chemistry and electrolyte levels was also conducted. Pleurodesis was achieved via a chest tube on the fourth day of hospitalization when drainage ceased. Then, 50 mL of autologous blood was obtained on the fourth day of admission. Immediately, blood extracted from the patient was injected into the pleural space through the chest tube. Then, it was removed on the same day. The patient was discharged on the seventh day of admission without complications. At 24 months of follow-up, she had no further recurrence of effusion. Written informed consent was obtained from the patient to participate in the present study.

Discussion

Although benign in nature, HH might cause significant social, emotional, and professional disabilities in patients who generally cannot be adequately treated with conservative methods (3). Conservative methods are generally used only for patients with mild symptoms. Thus, the majority of patients with mild to severe HH will sooner or later be recommended for surgery as precise treatment. There is no doubt that thoracoscopic sympathectomy has provided a highly reliable solution for HH. This has been shown in a clinical report of successful control of symptoms by surgery in more than 95% of patients (2). The overall rate of complications is less than 5%, and these are minor complications. Chylothorax is an extremely uncommon complication due to thoracoscopic sympathectomy but continues to be a formidable clinical problem of

any thoracic surgical practice. In the English literature, eight cases of chylothorax after sympathectomy have been reported, one via transaxillary sympathectomy and seven via thoracoscopy.

Chylothorax is the accumulation of lymphatic fluid in the pleural cavity due to ductus thoracicus and damage to the lymphatic vessels. Postoperative chylothorax that develops after thoracic sympathectomy is a rare case and generally can be observed in 0.5%-2.5% of patients after cardiac and thoracic surgeries. Traditional conservative management of chylothorax has a failure rate of up to 48%, especially in high-output fistulae (4). Chylothorax was observed in our patient. The route of the thoracic duct varies in 40%-60% of individuals. Anatomical variations make it more susceptible to accidental injury during thoracic surgery. Its route is anomalous and unpredictable (5).

Typically, postoperative chylothorax occurs 2 to 10 days after surgery. However, in our case, it occurred in a much shorter time, i.e., only 4 h. The most common symptoms in patients with chylothorax are shortness of breath and cough. None of these symptoms were exhibited in our patient. However, she had chest pain, which is rarely observed in patients with chylothorax.

Current treatments of chylothorax include conservative, surgical, and radiation therapies. The management of postsurgical chylothorax is guided by a set of principles rather than a strict algorithm. These principles include efficient drainage of the effusion, cessation of flow through the thoracic duct, and obliteration of the pleural space (6). Pleural obliteration is also used to prevent prolonged air leakage and fluid accumulation in the pleural space. A wide variety of sclerosing agents are used for this procedure. Among these, autologous blood, which is less toxic and injurious to the lung tissue than traditional chemical substances, has been used since 1987 in order to close the pleural space and prevent air leaks. Although the underlying mechanism is controversial and there is no standardized administration amount and method, usually, numerous case reports, series, and retrospective or prospective studies have reported successful results (7). Pleurodesis compared with surgery has significantly increased the success rate, decreased the ICU stay and need for surgery, and reduced the overall hospital stay associated with decreased mortality (8, 9). Its success has encouraged us. We believe that it can be used for the treatment of chylothorax because it is easy to apply, painless, comfortable, fast, and cheap, without requiring analgesia or sedation during pleurodesis. We easily administered pleurodesis, and the chest tube was clamped for 2 h at the bedside without any complications (7-9). The first treatment option is surgery only for a small group of patients. Conservative treatments that should always be kept in mind are preferred by the majority of patients and successful in only half of the cases. Although the criteria for conservative treatment of thoracic duct injury has been described in the literature, the choice for the most appropriate treatment for patients is based on the clinician's experience and the patient's incomparable condition (6).

Conclusion

No similar case of postoperative chylothorax treated with pleurodesis using autologous blood has been found in the English literature. According to anatomical variations, the ductus thoracicus is susceptible to injury even in the hands of an experienced surgeon.

In case an injury has occurred shortly after thoracic sympathectomy, autologous blood pleurodesis is an effective treatment for chylothorax. This procedure is safe and cheap and can be easily performed at the bedside.

Informed Consent: Written informed consent was obtained from patient who participated in this study.

Peer-review: Externally peer-reviewed.

Author Contributions: Concept - M.Ç., H.E., T.T.B., S.G.Ç.; Design - M.Ç., H.E., T.T.B., S.G.Ç.; Supervision - M.Ç., H.E., T.T.B., S.G.Ç.; Resource - M.Ç., H.E., T.T.B., S.G.Ç.; Materials - M.Ç., H.E., T.T.B., S.G.Ç.; Data Collection and/or Processing - M.Ç., S.G.Ç.; Analysis and/or Interpretation - M.Ç., S.G.Ç.; Literature Search - M.Ç., S.G.Ç.; Writing - M.Ç., S.G.Ç.; Critical Reviews - M.Ç., S.G.Ç.

Conflict of Interest: Authors have no conflicts of interest to declare.

Financial Disclosure: The authors declared that this study has received no financial support.

Hasta Onamı: Yazılı hasta onamı bu çalışmaya katılan hastadan alınmıştır.

Hakem Değerlendirmesi: Dış Bağımsız.

Yazar Katkıları: Fikir - M.Ç., H.E., T.T.B., S.G.Ç.; Tasarım - M.Ç., H.E., T.T.B., S.G.Ç.; Denetleme - M.Ç., H.E., T.T.B., S.G.Ç.; Kaynaklar - M.Ç., H.E., T.T.B., S.G.Ç.; Malzemeler - M.Ç., H.E., T.T.B., S.G.Ç.; Veri Toplanması ve/veya işleme - M.Ç., S.G.Ç.; Analiz ve/veya Yorum - M.Ç., S.G.Ç.; Literatür taraması - M.Ç., S.G.Ç.; Yazıyı Yazan - M.Ç., S.G.Ç.; Eleştirel İnceleme - M.Ç., S.G.Ç.

Çıkar Çatışması: Yazarların beyan edecek çıkar çatışması yoktur.

Finansal Destek: Yazarlar bu çalışma için finansal destek almadıklarını beyan etmişlerdir.

References

1. Macía I, Moya J, Ramos R, Rivas F, Urena A, Rosado G, et al. [Primary hyperhidrosis. Current status of surgical treatment]. *Cir Esp* 2010; 88: 146-51. [Article in Spanish] [\[CrossRef\]](#)
2. Sugimura H, Spratt EH, Compeau CG, Kattail D, Shargall Y. Thoracoscopic sympathetic clipping for hyperhidrosis: long-term results and reversibility. *J Thorac Cardiovasc Surg* 2009; 137: 1370-6. [\[CrossRef\]](#)
3. Reisfeld R, Nguyen R, Pnini A. Endoscopic thoracic sympathectomy for hyperhidrosis: experience with both cauterization and clamping methods. *Surg Laparosc Endosc Percutan Tech* 2002; 12: 255-67. [\[CrossRef\]](#)
4. Kumar S, Kumar A, Pawar DK. Thoracoscopic management of thoracic duct injury: Is there a place for conservatism? *J Postgrad Med* 200; 50: 57-9.
5. Apiliogullari B, Esmé H, Yoldas B, Duran M, Duzgun N, Calik M. Early and midterm results of single-port video-assisted thoracoscopic sympathectomy. *Thorac Cardiovasc Surg* 2012; 60: 285-9. [\[CrossRef\]](#)
6. Stager V, Le L, Wood RE. Postoperative chylothorax successfully treated using conservative strategies *Proc (Bayl Univ Med Cent)* 2010; 23: 134-8 [\[CrossRef\]](#)
7. Muruganandan, S, Kumar S, Lee, YCG. Blood Patch for Pneumothorax: A Literature Review. *Cur Pulmonol Rep*, 2017; 6: 30-8. [\[CrossRef\]](#)
8. Alamdari DH, Asadi M, Rahim AN, Maddah G, Azizi S, Shahidsales S, et al. Efficacy and Safety of Pleurodesis Using Platelet-Rich Plasma and Fibrin Glue in Management of Postoperative Chylothorax After Esophagectomy. *World J Surg* 2018; 42: 1046-55. [\[CrossRef\]](#)
9. Akin H, Olcmen A, Isgorucu O, Denizkiran I, Dincer I. Approach to patients with chylothorax complicating pulmonary resection. *Thorac Cardiovasc Surg* 2012; 60: 135-9. [\[CrossRef\]](#)

Cite this article as: Çalık M, Esmé H, Bekçi TT, Göknil Çalık S. Chylothorax: A Rare Complication of Endoscopic Thoracic Sympathectomy *İstanbul Med J* 2018; 19: 167-9.