

Received: 2018.04.08
Accepted: 2018.03.05
Published: 2018.08.21

Role of Ozone Therapy in Preventing Testicular Damage in an Experimental Cryptorchid Rat Model

Authors' Contribution:
Study Design A
Data Collection B
Statistical Analysis C
Data Interpretation D
Manuscript Preparation E
Literature Search F
Funds Collection G

ABDEFG 1 **Şenol Biçer**
BCDEF 2 **Cebrail Gürsul**
BDEFG 3 **İlyas Sayar**
BDEG 4 **Orhan Akman**
CEF 1 **Seçil Çakarlı**
BDG 5 **Merve Aydın**

1 Department of Pediatric Surgery, Medical School of Erzincan University, Erzincan, Turkey
2 Department of Physiology, Medical School of Erzincan University, Erzincan, Turkey
3 Department of Pathology, Medical School of Erzincan University, Erzincan, Turkey
4 Faculty of Veterinary Sciences, Ataturk University, Erzurum, Turkey
5 Department of Medical Microbiology, Medical School of KTO Karatay University, Konya, Turkey

Corresponding Author: Şenol Biçer, e-mail: drsenolbicer@gmail.com

Source of support: This research was supported by Erzincan University Unit of Scientific Projects (2015, SAG-A-080715-0161), Erzincan, Turkey

Background: Cryptorchidism is the most common developmental abnormality of the male reproductive system. If left untreated, it results with infertility and testicular cancer. According to current evidence, surgery is the mainstay of treatment, and hormonal therapy approaches are still under investigation. For the protection of testicular functions, antioxidants have emerged as novel options. This study aimed to evaluate the protective properties of ozone, a strong antioxidant, on testicular tissue.

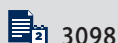Material/Methods: Thirty-five male Wistar-albino rats, 1-month-old, were used for the study. Groups were formed as follows: 1) control, 2) sham surgery (cryptorchidism), 3) cryptorchidism plus ozone, 4) cryptorchidism plus human chorionic gonadotropin (hCG), and 5) ozone plus hCG. Surgical procedures were performed on all rats except the control group. All rats except the control group were used to create an experimental cryptorchidism model, and left testes of animals were surgically placed into the abdomen. After 1 month of surgery, groups 3, 4, and 5 were given corresponding treatments intraperitoneally for 4 weeks. At the end of the study period, testicular atrophy index (TAI) and testicular sperm motility (TSM) were assessed and biochemical, histopathological, and immunohistochemical tests were performed.

Results: TAI and TSM were higher in the ozone, hCG, and ozone plus hCG groups than in the sham surgery group ($p=0.001$). TSM in the ozone group was significantly higher than in the hCG and ozone plus hCG groups. In biochemical analyses, the parameters of oxidative stress (GPx1, MDA, CAT, GSH, SOD) indicated increased oxidative activity in cryptorchidism, which was resolved by applying ozone and hCG ($p=0.001$). In addition, apoptotic markers, Caspase 3 and bcl-2 were significantly decreased by applying ozone and hCG ($p=0.001$).

Conclusions: Results of this study suggest that ozone therapy, either as a single agent or in combination with hCG, is a promising approach for protection of testicular functions.

MeSH Keywords: Antioxidants • Chorionic Gonadotropin, beta Subunit, Human • Cryptorchidism • Fertility • Ozone

Full-text PDF: <https://www.medscimonit.com/abstract/index/idArt/910459>



3098



4



2



33



Background

Cryptorchidism is the unilateral or bilateral absence of testicles in the scrotum, and it is reported as the most common developmental abnormality of the male genitalia [1]. It is present in more than 1% of boys over 3 months of age [2]. If not treated properly, progressive histological and functional deterioration of testicles eventually result in infertility [3] and testicular cancer [4]. Several factors have been suggested to play a role in the development of this disorder, but the exact mechanism is unknown [5]. According to currently available evidence, cryptorchidism has a multifaceted etiology that includes genetic, endocrine, anatomical, mechanical, and environmental factors [6]. The interaction of these factors results with undescended testicles, which can be unilateral or bilateral.

Many previous studies evaluated the outcomes of unilateral and bilateral cryptorchidism, and the majority of them reported similar results, showing that bilateral undescended testes are associated with lower fertility rates when compared to unilateral cryptorchidism [7,8]. Some studies even revealed that patients with unilateral cryptorchidism have similar paternity rates as the general population [9]. Although some degree of decreased sperm density is present in patients with cryptorchidism, it is regardless of being unilateral or bilateral. According to some previous studies, 17% of unilateral cryptorchidism cases show decreased sperm density, while this rate increases to 50% in bilateral cryptorchidism cases [10,11].

The histological and functional deterioration of testicles should be corrected with appropriate interventions to preserve the fertility of patients, and current evidence suggests that corrective surgery is the mainstay treatment in these cases [2]. However, some other approaches, such as the addition of hormonal therapy to surgery, are still under investigation [12]. Some authors suggest that administering medication is controversial, but some others report favorable outcomes with the use of hormonal therapy in addition to surgery [13].

Current evidence suggests that maintenance of testicular functions is crucial to achieve successful long-term fertility outcomes in patients with cryptorchidism. With regard to these efforts, this study aimed to evaluate the protective properties of ozone, a strong antioxidant, on testicular tissue of an experimental cryptorchid rat model.

Material and Methods

This study was designed to evaluate the effects of ozone, an antioxidant, on testicles of rats in an experimental cryptorchidism model. Histopathological evaluations included hematoxylin-eosin staining and Johnsen scoring. Oxidative damage

was evaluated by biochemical assays, including MDA, SOD, CAT, GSH, and GPx1. Apoptotic changes were evaluated by Bcl-2 and Caspase-3, and immunohistochemical evaluations included Caspase-3 staining. The Ethics Committee for Animal Experiments of the University of Atatürk, Erzurum, Turkey approved this study (05.06.2015-129). This research was supported by Erzincan University Unit of Scientific Projects (2015), Erzincan, Turkey.

Study groups

Thirty-five male Wistar-albino rats, one-month-old, weighing 40–55 grams were randomly allocated into 5 study groups. Each group included 7 animals. The rats used in the experiments were obtained from Atatürk University Medical Practice and Research Center and were housed in plastic well-aerated breeding cages at a constant temperature of $21\pm 1^{\circ}\text{C}$, with a 12-h dark 12-h light cycle. Rats were fed using standard pellet chow and tap water ad libitum.

The study groups were formed as follows:

- **Group 1:** Control group
- **Group 2:** Sham surgery to develop cryptorchidism only
- **Group 3:** Cryptorchidism and ozone treatment
- **Group 4:** Cryptorchidism and human chorionic gonadotropin (hCG) treatment
- **Group 5:** Cryptorchidism and ozone and hCG treatment

Cryptorchidism model

Unilateral cryptorchidism models have been used in previous studies and no problems have been reported after surgery. Each rat was anesthetized using intraperitoneal ketamine hydrochloride (80 mg/kg) and xylazine hydrochloride (10 mg/kg). An incision was made in the inguinoscrotal region following scrotal shaving. Left gubernaculum was separated and the external inguinal ring was exposed. Then, gubernaculum was displaced into the abdomen, and the external ring was reclosed [14]. The surgical model is presented in Figure 1A, and a macroscopic view of the testicles at the end of the study is shown in Figure 1B.

Application of ozone and human chorionic gonadotropin

A generator (OZONOSAN Photonik 1014, Hansler GmbH; Nordring & Iffezheim, Germany) was used to produce ozone (O_3). The flow rate of ozone was kept constant at a concentration of 60 mg/mL; 97% oxygen plus 3% ozone gas mixture at 3 L/min. The mixture of ozone and oxygen was applied intraperitoneally to rats for 4 weeks at a single dose of 2 mL daily, and hCG (Pregnyl 1500 IU amp, Organon) was applied intraperitoneally twice a week at a dose of 100 IU/kg in 2 mL of saline for 4 weeks.

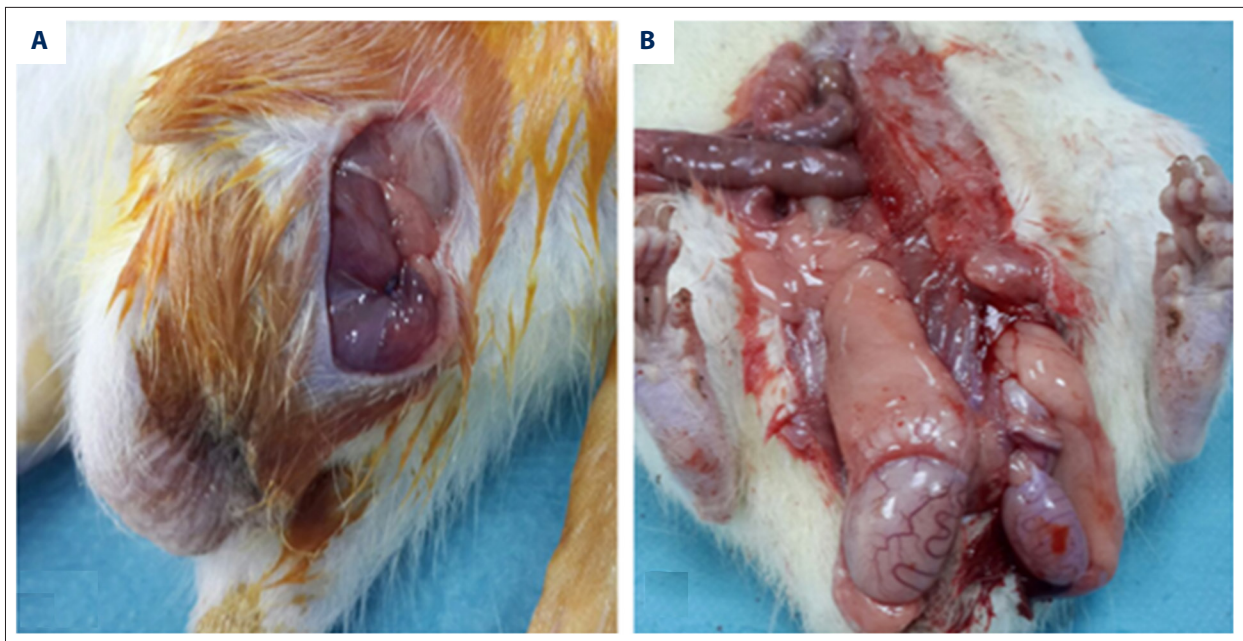


Figure 1. Surgical cryptorchidism model – (A) initial surgery; (B) macroscopic view of the testes at the end of the study.

Sample collection

Both testes of the animals were removed under ketamine anesthesia, and the epididymis was removed. Weight and dimensions of the testicles were measured, and testicular atrophy index was calculated [15]. A portion of the samples was stored in 10% buffered formaldehyde solution for histopathological evaluation, and another portion was kept at -80°C for biochemical analysis.

Evaluation of sperm motility

Sperm analysis was conducted on a hot plate at $35.5 \pm 0.5^{\circ}\text{C}$ and in a water bath to ensure vitality of the samples. Blood remnants were removed from the caudal epididymis and each cauda epididymis was cut from 5–7 sites. The samples were kept in saline for 15 min, and then the cauda epididymis was squeezed with a clamp to release all sperm into the saline solution. Each 1 part of sperm was diluted in 4 parts of saline in an Eppendorf tube, and sperm motility was assessed under a light microscope with an $\times 20$ objective in 2 separate fields at a minimum of 10 counting areas according to the method of Akman et al. [16].

Biochemical analyses

For biochemical analysis, serum was separated from the blood after allowing it to stay in a test tube for about 30 min, then it was centrifuged at 3000 rpm for 20 min and the sample was stored at -20°C until used for the ELISA assays. For the analysis of tissue samples, tissues were rinsed in ice-cold phosphate-buffered saline (PBS) ($\text{pH}=7.2\text{--}7.4$) and weighed before

homogenization. The tissues were minced into small pieces and were homogenized by grinding in PBS ($\text{pH}=7.2\text{--}7.4$). Then, the homogenates were centrifuged for 20 min at 2000–3000 rpm. The supernatant was removed, aliquoted, and stored at -20°C until used for the ELISA assays.

Tissue GPx1, MDA, CAT, GSH, SOD, CASPASE 3 levels, and serum BCL 2 level were quantified using an ELISA kit (Shanghai Sunred Biological Technology Co., Ltd, Shanghai, China). All assay procedures were carried out according to the manufacturer's instructions. The sensitivity levels of these assays for CAT, SOD, MDA, GSH, Caspase-3, Bcl-2, and GPx1 were 0.52 ng/mL, 0.016 ng/mL, 0.024 nmol/mL, 10.25 mg/L, 0.01 ng/mL, 0.026 ng/mL, and 0.23 ng/mL, respectively. The absorbance of standards and samples were obtained at 450 nm wavelength using an Epoch spectrophotometer (BioTek Instruments, Inc., Winooski, VT, USA). A standard curve was plotted with concentration on x-axis and absorbance on y-axis to determine the levels of CAT (ng/mL), SOD (ng/mL), MDA (nmol/mL), GSH (mg/L), Caspase-3 (ng/mL), Bcl-2 (ng/mL), and GPx1 (ng/mL).

Histopathological evaluation: Johnsen scoring

For histological analysis, the formalin-fixed skin samples were prepared for paraffin sections. Then, $4\text{-}\mu\text{m}$ sections were made and placed on slides. These slides were stained with hematoxylin and eosin (H&E). Johnsen scoring system was used for the quantitative assessment of germ cell types [17]. The level of sperm maturation is graded between 1 and 10, with 10 representing complete spermatogenesis with many spermatozoa. Figure 2 represents sample sections from Johnsen scoring.

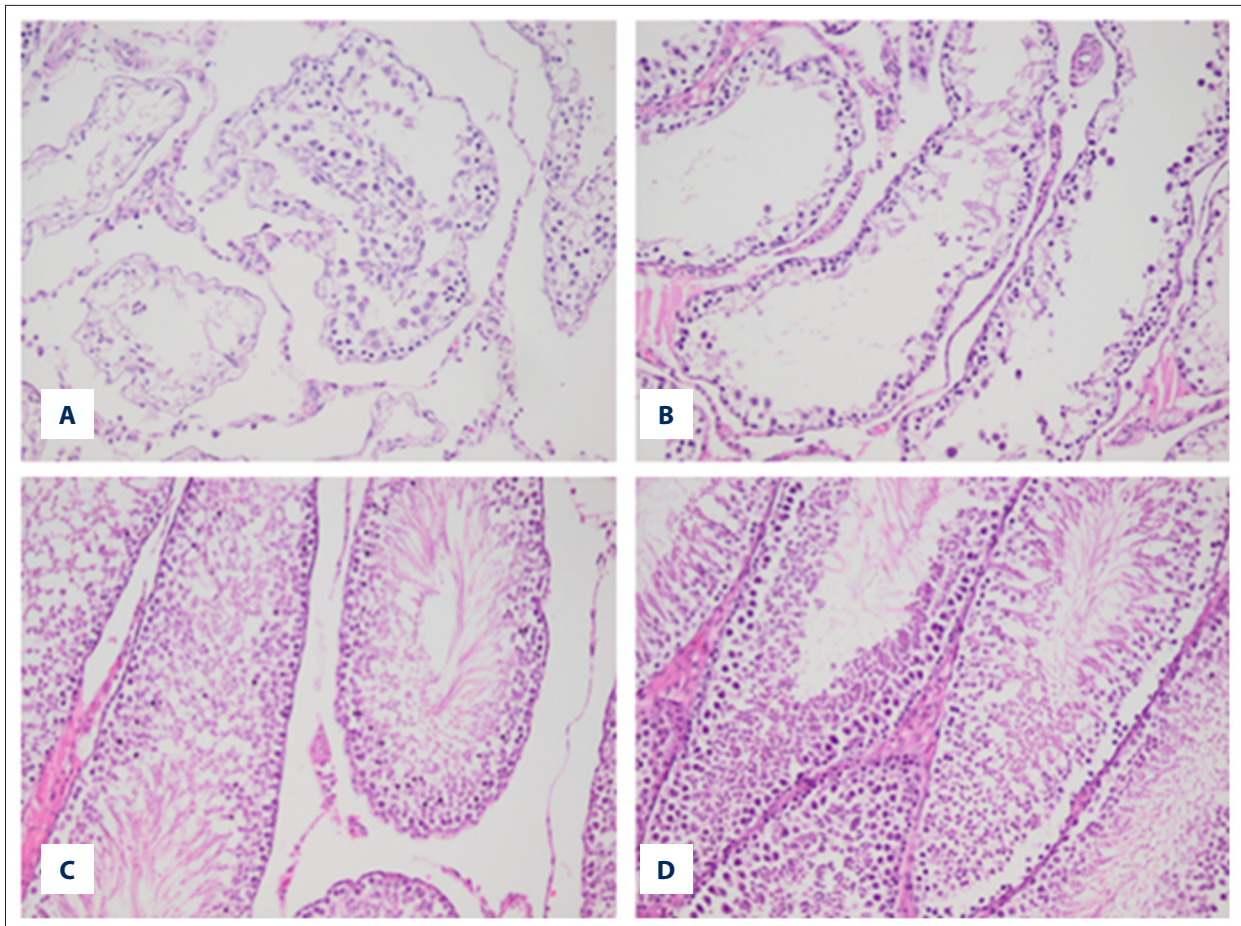


Figure 2. Sections of samples with different Johnsen scores – (A) Johnsen score 3; (B) Johnsen score 5; (C) Johnsen score 8; (D) Johnsen score 10.

Immunohistochemical evaluation

Four-micron sections were taken for positively-charged slides by selecting appropriate formalin-fixed, paraffin-embedded tissue sections. Then, Caspase-3 biomarker was studied using a fully automated IHC staining device (Leica Bond-Max, Melbourne, Australia). Slides of these cases were evaluated under light microscopy (Olympus BX53, Tokyo, Japan). These evaluations were carried out semiquantitatively. Caspase-3 expression was classified according to the number of positively stained cells per 1000 counted cells. When evaluating immunostaining, nuclear staining of tumor cells was assessed. The percentage of positive cells was scored according to the method of Nakagawa et al., as follows: 0=negative (less than 5% stained); 1+=weak staining (between 5% and 25% stained); 2+=moderate staining (between 25% and 50% stained); and 3+=strong staining (more than 50% stained) [18].

Statistical analysis

Data analysis was performed with SPSS 20 Software (IBM Corp. Released 2011. IBM SPSS Statistics for Windows, Version 20.0. Armonk, NY: IBM Corp.). Data are presented as mean and standard deviation. Normal distribution and variance homogeneity of variables were evaluated with Shapiro-Wilk and Levene tests, respectively. Multiple group comparisons between 3 and more independent groups were analyzed with one-way ANOVA or Kruskal-Wallis tests, according to the results of normality tests. Corresponding tests used for post hoc pairwise comparisons in case of statistical significance in multiple group comparisons were Tukey HSD and Bonferroni-Dunn, respectively. A two-tailed statistical significance level was set at $p < 5\%$.

Results

A total of 35 rats without missing data, with 7 rats in each study group, were included in the analyses. The testicular atrophy index and testicular sperm motility findings are presented

Table 1. Testicular atrophy index and testicular sperm motility in study groups.

	Right	Left
	Mean ±SD	Mean ±SD
Testicular atrophy index		
Control	0.7±0.14	0.69±0.12
Cryptorchidism	0.46±0.04	0.23±0.14
Ozone	0.57±0.09	0.45±0.11
hCG	0.52±0.07	0.41±0.1
Ozone plus hCG	0.54±0.1	0.44±0.12
p	0.001	0.001
Testicular sperm motility		
Control	64.29±7.87	64.29±7.87
Cryptorchidism	50±18.26	10±19.15
Ozone	51.43±6.9	20±18.26
hCG	45.71±11.34	22.86±20.59
Ozone plus hCG	44.29±16.18	17.14±18.9
p	0.043	0.001

in Table 1. Accordingly, TAI, both in the displaced left testicles ($p=0.001$) and in the right testes ($p=0.001$), was found to be significantly different between study groups. Similarly, TSM was found to be significantly different between study groups in left ($p=0.001$) and right ($p=0.043$) testicles. Post hoc pairwise comparisons revealed that the highest and lowest values of TAI in both testes were in the control and sham surgery groups, respectively. The highest and lowest values of TSM in the left (operated) testes were in the control and sham surgery groups, respectively. TSM in the ozone, hCG, and ozone plus hCG groups were significantly higher than that in the sham surgery group. In right testes, TSM in the ozone group was significantly higher than that in the hCG and ozone plus hCG groups.

Biochemical evaluations for oxidative damage are summarized in Table 2. Accordingly, GPx1 ($p=0.001$), MDA ($p=0.002$), CAT ($p=0.003$), GSH ($p=0.004$), and SOD ($p=0.011$) values in the right testes significantly differed between study groups. The lowest GPx1, CAT, GSH, and SOD values and the highest MDA levels were in the sham surgery group, and the lowest MDA levels were in the ozone plus hCG group. However, in the operated left testicles, only GPx1 values were significantly different between the groups ($p=0.001$), while the remaining indicators of oxidative damage were similar.

Caspase-3 and Bcl-2 values indicating the apoptotic changes in the testicles are presented in Table 3. Both indicators

Table 2. Evaluation of oxidative damage in study groups.

	Right	Left
	Mean ±SD	Mean ±SD
GPx1		
Control	24.73±6.97	106.73±63.02
Cryptorchidism	11.51±19.52	26.29±24.17
Ozone	30.28±12.89	39.82±23.34
hCG	36.79±10.08	40.07±30.38
Ozone plus hCG	22.03±20.76	34.16±21.67
p	0.001	0.001
MDA		
Control	3.98±2.98	6.36±5.36
Cryptorchidism	4.49±2.53	6.87±4.91
Ozone	2.581±1.94	2.819±4.32
hCG	3.266±1.97	3.504±4.35
Ozone plus hCG	1.945±0.96	2.183±3.34
p	0.002	0.175
CAT		
Control	53.99±2.98	56.37±5.36
Cryptorchidism	35.16±38.31	37.54±40.69
Ozone	66.07±12.54	68.45±14.92
hCG	72.92±38.32	75.3±40.7
Ozone plus hCG	59.71±37.25	62.09±39.63
p	0.003	0.175
GSH		
Control	265.93±111.37	368.12±113.75
Cryptorchidism	237.67±73.16	260.05±75.54
Ozone	278.01±314.62	380.08±317
hCG	284.86±367.25	386.93±369.63
Ozone plus hCG	271.65±174.48	373.72±176.86
p	0.004	0.293
SOD		
Control	4.91±0.86	3.29±3.24
Cryptorchidism	1.53±3.31	1.91±5.69
Ozone	2.674±4.4	2.912±6.78
hCG	3.359±3.36	3.597±5.74
Ozone plus hCG	2.038±2.98	2.276±5.36
p	0.011	0.432

GPx1 – glutathione peroxidase-1; MDA – malondialdehyde; CAT – catalase; GSH – glutathione; SOD – superoxide dismutase.

Table 3. Evaluation of apoptosis in study groups.

	Right	Left
	Mean ±SD	Mean ±SD
Caspase-3		
Control	2.27±0.55	1.81±0.74
Cryptorchidism	4.53±0.41	3.17±1.76
Ozone	1.89±0.48	2.21±1.06
hCG	2.86±0.74	2.64±1.65
Ozone plus hCG	1.52±0.89	2.47±1.26
p	0.001	0.001
Bcl-2		
Control	1.86±0.38	3.19±1.62
Cryptorchidism	2.12±0.41	6.11±2.62
Ozone	1.64±0.57	4.67±3.64
hCG	1.93±0.94	4.88±1.3
Ozone plus hCG	1.31±1.06	3.84±1.11
p	0.001	0.001

were found to be significantly different between the study groups. The highest levels of both parameters were found in the sham surgery group for both testicles, while the values were significantly lower in the ozone, hCG, and ozone plus hCG-treated groups.

The lowest scores for caspase staining were found in the ozone-treated group in both testes. The highest Johnsen scores were found in the control group in left testes, while the score was the same as for the non-operated control group in right testes. The results of the histopathological and immunohistochemical evaluations in the study groups are summarized in Table 4.

Discussion

This study aimed to evaluate the effects of ozone, which is a highly effective antioxidant, on preserving testicular functions in cryptorchidism. The role of ozone on testicular functions was evaluated both as a single agent and in combination with hCG, which is the most prevalently used medication in the treatment of undescended testes. One of the most striking findings of this study was the decrease in testicular atrophy index and sperm motility in the contralateral testes, a finding that was also reported by previous studies. With regard to the bilateral risk in testicular functions, adding different modalities to surgery is important to preserve functions of the contralateral descended testis in unilateral cryptorchidism.

Table 4. Immunohistochemical and histopathological evaluations in study groups.

	Right	Left
	Mean ±SD	Mean ±SD
Caspase		
Control	0.143±0.378	0.286±0.488
Cryptorchidism	2±0.816	1±0.577
Ozone	0.714±0.488	0.429±0.535
hCG	1.286±0.488	0.857±0.378
Ozone plus hCG	1.143±0.378	0.714±0.488
p	0.001	0.04
Johnsen score		
Control	9.857±0.378	9.857±0.378
Cryptorchidism	9.429±0.535	5.429±2.573
Ozone	9.857±0.378	9.143±0.9
hCG	9.714±0.488	7.857±1.069
Ozone plus hCG	9.286±0.756	8±1.528
p	0.04	0.001

Oxidative stress in cryptorchidism can be evaluated by analyzing biochemical parameters like SOD or GPx, which act as enzymatic cellular defense mechanisms, or by MDA levels, a lipoperoxidative degradation product [19]. A previous study by Surer et al. reported that free radicals were increased and SOD levels were significantly decreased when compared with the control group in their experimental study of a testicular fixation model [20]. Similarly, oxidative parameters were increased and antioxidative parameters were decreased in both testes in our cases, but these changes were more prominent in the contralateral testes. One possible explanation for this lateralization difference might be tissue hypoxia in the undescended testes, which might have deteriorated blood flow in testicles, consequently affecting the contralateral descended testes [20]. A possible outcome of increased oxidative stress and elevated production of end-products is increased apoptosis, which can be determined by immunohistochemical evaluations; caspase-3 and bcl-2 levels were analyzed in our study. Caspase activation is known as a hallmark of almost all apoptotic systems [21], and detecting caspase-3 activity in cells is a unique indicator of apoptosis. Bcl-2, on the other hand, is a member of the Bcl-2 family that regulates apoptotic signals, and bcl-2 is a pro-survival subfamily member [22]. In our study, we found that caspase-3 and bcl-2 levels were increased in our samples. This suggests an increased apoptotic activity and a counterbalancing anti-apoptotic activity. Since apoptosis is a natural mechanism involved in spermatogenesis, increased

levels of these indicators in comparison to the control group suggests contribution of additional factors in increasing levels of apoptosis. This mechanism is highly likely to be increased oxidative stress caused by tissue damage. One of the most prominent markers of testicular damage is the decreased percentage of motile spermatozoa, which we also observed in our cryptorchidism model. Testicular sperm motility was significantly increased by the application of ozone and hCG in our samples. Combined use of ozone and hCG also increased sperm motility, but when compared with solitary application of these agents, the effect was smaller.

The hypothesis underlying this study was that ozone treatment would improve oxidative stress and contribute to preservation of testicular functions in cryptorchidism. It was shown that cryptorchidism significantly reduced testicular atrophy index and sperm motility, but ozone treatment significantly recovered these parameters in the intervention groups. Also, immunohistochemical analyses including Caspase staining and histopathological evaluations performed using Johnsen scoring revealed that ozone application significantly improved outcomes when compared to the sham surgery group. The contribution of ozone in these outcomes was probably the inhibition of oxidative damage, consequently leading to increased apoptosis. Biochemical analyses in our study also supported this hypothesis and showed significant improvements in oxidative stress indicators in ozone-treated groups. These beneficial antioxidant effects of ozone were also reported by other studies [23,24].

To the best of our knowledge, the role of ozone therapy in testicular functions were only evaluated by 2 previous studies. Alpcan et al. evaluated the effects of ozone therapy on apoptosis, eNOS, and iNOS immunoreactivity in rat testis tissue following vasectomy [25]. According to their results, the authors suggested that ozone administration had beneficial effects on oxidative damage, but could also be harmful if applied to healthy subjects. The second study, performed by Mete et al., evaluated the route of administration of ozone therapy on the outcomes in rat testes in an experimental torsion model [26]. According to their results, intratesticular application provided higher efficacy when compared to the intraperitoneal route. Nevertheless, they also stated that both applications were beneficial to improve oxidative stress in torsion cases. In our study, we used the intraperitoneal route of administration, and similarly favorable outcomes were observed. The most notable element of our study is the choice of the disease model, cryptorchidism, which is the most frequent developmental abnormality of the male genitals. The high prevalence of the disease necessitates efficient interventions and treatments to preserve future fertility in those patients, and according to our results, besides the currently available treatment options, ozone therapy is a promising approach in the treatment of cryptorchidism.

Another implication of our study is the contribution of hCG to the outcomes, either used as a single agent or in combination with ozone. It was shown that hCG had a positive contribution on outcomes, as reflected by increased sperm motility in displaced testes. The ozone, hCG, and ozone plus hCG groups were statistically similar in increasing sperm motility, and all of them were superior to the sham surgery group. The highest percentage of motility was observed in hCG-treated samples, followed by ozone and hCG plus ozone groups.

The data in the literature on use of hCG in the treatment of cryptorchidism is controversial regarding outcomes [27]. Some studies reported that hCG treatment immediately increases the levels of apoptosis when compared with the cases that underwent surgical correction without any prior hCG treatment [28,29]. One possible explanation of the conflicting results in the literature might be the difference in applied doses in different studies. The effect of hormonal therapy on the treatment of cryptorchidism is still under debate. Hormonal therapy is applied in selected cases of cryptorchidism and retractile testis [30, 31]. Currently, the World Health Organization recommends using 250 IU in boys <1 year of age twice a week for 5 weeks, 500 IU in those of ages 1–5 years twice a week for 5 weeks, and 1000 IU in those of ages >5 years twice a week for 5 weeks, and there are also some other recommendations from different groups [32]. The doses of hCG that we used in our study were compatible with the recommendations of the WHO, and we conclude that the positive effects of hCG on testicular sperm motility were related with this dose regimen. Nevertheless, there may be another mechanism for the treatment failure with hCG regarding descent of the testes to a normal scrotal position. A study by Giannopoulos et al. reported that descent of testes is limited by factors like anatomical alterations of the inguinal canal, epididymal abnormalities, and ectopic distal attachment of the ligamentum testis [33]. Regarding experimental approaches in cryptorchidism models, our results are in favor of hCG treatment, either as a single agent or in combination with ozone.

Conclusions

Cryptorchidism is a serious problem that should be treated properly to preserve fertility in later life. Currently available approaches are still under debate regarding efficacy. Since tissue damage and oxidative stress are prominent on displaced testes in cryptorchidism, antioxidant therapy can be efficacious in preserving testicular functions. Ozone treatment has emerged as a novel approach in this regard. On the basis of the results of the present study, we conclude that use of ozone therapy, either as a single agent or in combination with hCG, is effective in protection of testicular functions, which was supported by the increased sperm motility in our cases.

Acknowledgments

We would like to thank Ataturk University Experimental Research Center for help during the experimental study.

References:

1. Serrano T, Chevrier C, Multigner L et al: International geographic correlation study of the prevalence of disorders of male reproductive health. *Hum Reprod*, 2013; 28(7): 1974–86
2. Brucker-Davis F, Pointis G, Chevallier D et al: Update on cryptorchidism: Endocrine, environmental and therapeutic aspects. *J Endocrinol Invest*, 2003; 26(6): 575–87
3. Trussell JC, Lee PA: The relationship of cryptorchidism to fertility. *Curr Urol Rep*, 2004; 5(2): 142–48
4. Wood HM, Elder JS: Cryptorchidism and testicular cancer: Separating fact from fiction. *J Urol*, 2009; 181(2): 452–61
5. Ferlin A, Zuccarello D, Garolla A et al: Hormonal and genetic control of testicular descent. *Reprod Biomed Online*, 2007; 15(6): 659–65
6. Komarowska MD, Hermanowicz A, Debek W: Putting the pieces together: Cryptorchidism – do we know everything? *J Pediatr Endocrinol Metab*, 2015; 28(11–12): 1247–56
7. Gill B, Kogan S: Cryptorchidism. Current concepts. *Pediatr Clin North Am*, 1997; 44(5): 1211–27
8. Cobellis G, Noviello C, Nino F et al: Spermatogenesis and cryptorchidism. *Front Endocrinol (Lausanne)*, 2014; 5: 63
9. Lee PA: Fertility in cryptorchidism. Does treatment make a difference? *Endocrinol Metab Clin North Am*, 1993; 22(3): 479–90
10. Lee PA: Fertility after cryptorchidism: Epidemiology and other outcome studies. *Urology*, 2005; 66(2): 427–31
11. Fawzy F, Hussein A, Eid MM et al: Cryptorchidism and Fertility. *Clinical Medicine Insights: Reproductive Health*, 2015; 22(9): 39–43
12. Biers SM, Malone PS: A critical appraisal of the evidence for improved fertility indices in undescended testes after gonadotrophin-releasing hormone therapy and orchidopexy. *J Pediatr Urol*, 2010; 6(3): 239–46
13. Ong C, Hasthorpe S, Hutson JM: Germ cell development in the descended and cryptorchid testis and the effects of hormonal manipulation. *Pediatr Surg Int*, 2005; 21(4): 240–54
14. Dundar M, Kocak I, Culhaci N: A new experimental model for cryptorchidism: Inguinoscrotal approach. *Urol Res*, 2001; 29(3): 178–81
15. Yilmaz Ö, Akyol İ, Özyurt M et al: The influence of hormonal treatment with beta-human chorionic gonadotropin for cryptorchidism on future fertility in rats. *J Pediatr Urol*, 2015; 11(2): 92.e1–e4
16. Akman O, Özkanlar Y, Özkanlar S et al: Erythropoietin hormone and ACE inhibitor protect the sperm parameters of adult male rats against doxorubicin toxicity. *Kafkas Universitesi Veteriner Fakültesi Dergisi*, 2015; 21(6): 805–12
17. Zhang LT, Kim HK, Choi BR et al: Analysis of testicular-internal spermatic vein variation and the recreation of varicocele in a Sprague-Dawley rat model. *Andrology*, 2014; 2(3): 466–73
18. de Sousa FA, Paradella TC, Carvalho YR et al: Comparative analysis of the expression of proliferating cell nuclear antigen, p53, bax, and bcl-2 in oral lichen planus and oral squamous cell carcinoma. *Ann Diagn Pathol*, 2009; 13(5): 308–12
19. Mates JM, Perez-Gomez C, Nunez de Castro I: Antioxidant enzymes and human diseases. *Clin Biochem*, 1999; 32(8): 595–603
20. Surer I, Demirbag S, Ozturk H et al: Effects of testicular fixation on oxidative stress-related parameters in prepubertal rat testis. *Arch Androl*, 2006; 52(1): 71–78
21. Green DR: Apoptotic pathways: Paper wraps stone blunts scissors. *Cell*, 2000; 102(1): 1–4
22. Kiraz Y, Adan A, Kartal Yandim M et al: Major apoptotic mechanisms and genes involved in apoptosis. *Tumour Biol*, 2016; 37(7): 8471–86
23. Bocci V: Ozone as Janus: This controversial gas can be either toxic or medically useful. *Mediators Inflamm*, 2004; 13(1): 3–11
24. Martinez-Sanchez G, Perez-Davison G, Re L et al: Ozone as u-shaped dose responses molecules (hormetins). *Dose Response*, 2011; 9(1): 32–49
25. Alpcan S, Başar H, Aydos TR et al: Apoptosis in testicular tissue of rats after vasectomy: Evaluation of eNOS, iNOS immunoreactivities and the effects of ozone therapy. *Turk J Urol*, 2014; 40(4): 199–206
26. Mete F, Tarhan H, Celik O et al: Comparison of intraperitoneal and intratesticular ozone therapy for the treatment of testicular ischemia-reperfusion injury in rats. *Asian J Androl*, 2017; 19(1): 43–46
27. Ritzen EM: Undescended testes: A consensus on management. *Eur J Endocrinol*, 2008; 159(Suppl. 1): 87–90
28. Heiskanen P, Billig H, Toppari J et al: Apoptotic cell death in the normal and cryptorchid human testis: The effect of human chorionic gonadotropin on testicular cell survival. *Pediatr Res*, 1996; 40(2): 351–56
29. Dunkel L, Taskinen S, Hovatta O et al: Germ cell apoptosis after treatment of cryptorchidism with human chorionic gonadotropin is associated with impaired reproductive function in the adult. *J Clin Invest*, 1997; 100(9): 2341–46
30. Zivkovic D, Bica DG, Hadziselimovic F: Effects of hormonal treatment on the contralateral descended testis in unilateral cryptorchidism. *J Pediatr Urol*, 2006; 2(5): 468–72
31. Drabik G, Józsa T, Ruzsnavszky O et al: Correlation between the androgen receptor status of the appendix testis and the efficacy of human chorionic gonadotropin treatment in undescended testis. *Int Urol Nephrol*, 2015; 47(8): 1235–39
32. Abacı A, Çatlı G, Anık A et al: Epidemiology, classification and management of undescended testes: Does medication have value in its treatment? *J Clin Res Pediatr Endocrinol*, 2013; 5(2): 65–72
33. Giannopoulos MF, Vlachakis IG, Charissis GC: 13 Years' experience with the combined hormonal therapy of cryptorchidism. *Horm Res*, 2001; 55(1): 33–37

Conflict of interests

None.